

CARDIAC TAMPONADE

YOUR DECISION AND APPROACH

DR. AHMED SHAABAN
CONSULTANT CARDIOLOGY
DIRECTOR OF NON-INVASIVE LAB.
AL-WAKRAH HOSPITAL

- Transit passenger complaining of epigastric pain , vomiting and all body pain and feels hot no fever no chest pain and no SOB.
- she has attacks of palpitations and has H of depression.
- she has CT chest showing paracardiac mass.
- ECG shows sinus tachycardia 160 bpm, she took CCB and B Blocker today morning , BP 90/60 MMHG.

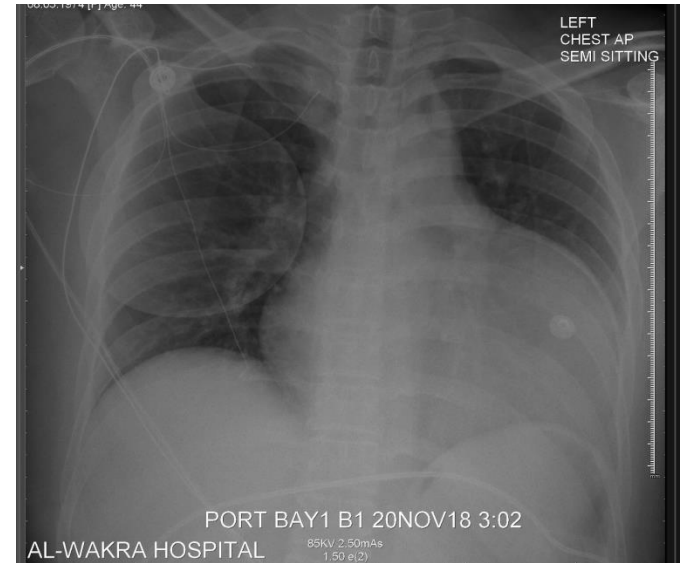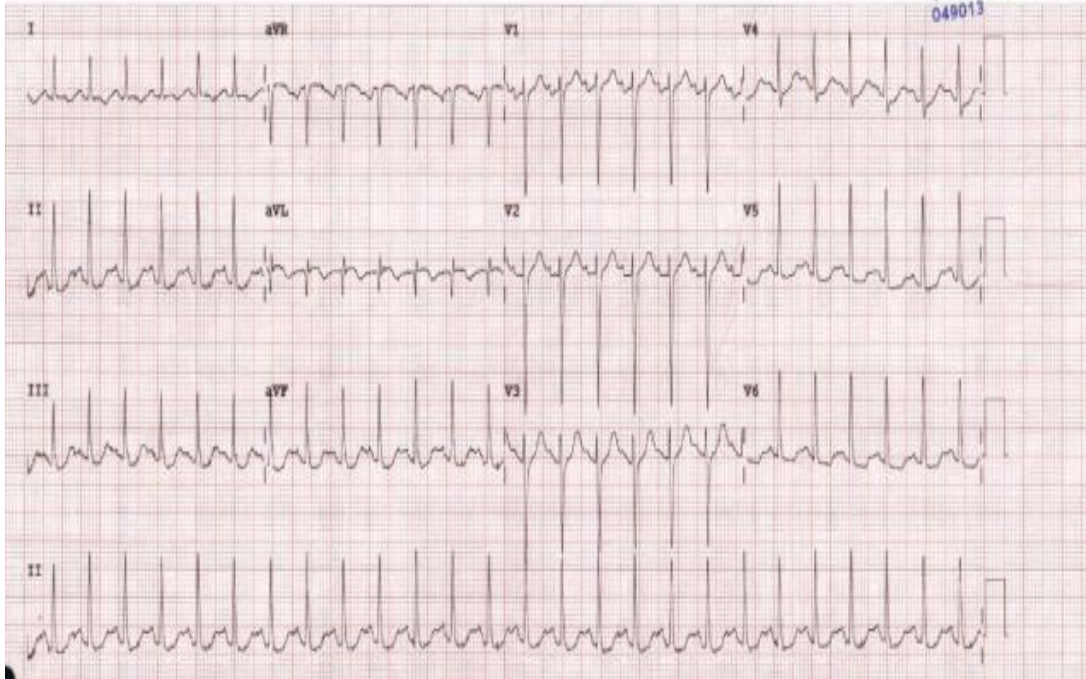
P 17
QRS 68
T 142
12 Lead; Standard Placement

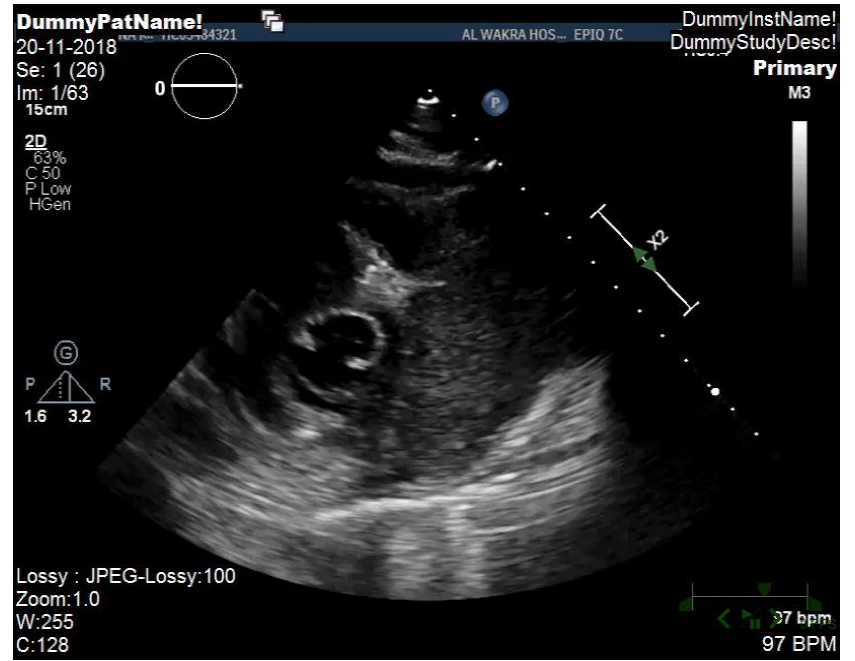
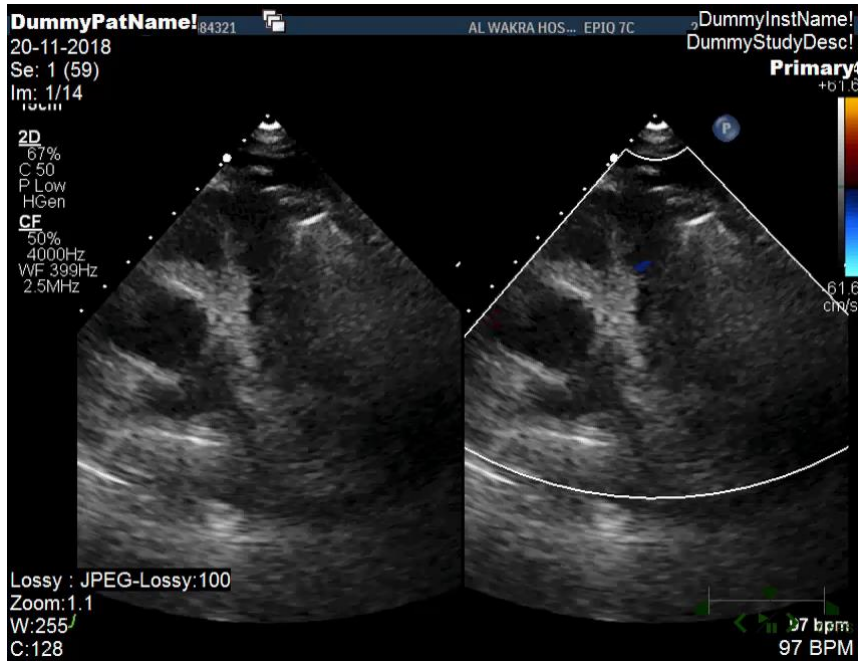
- ABNORMAL ECG -

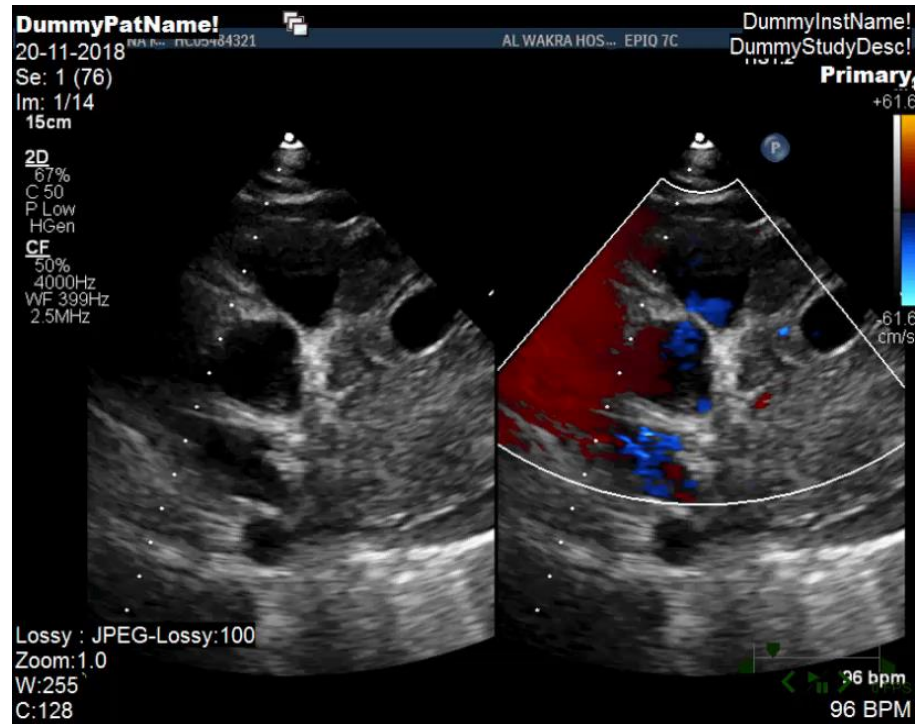
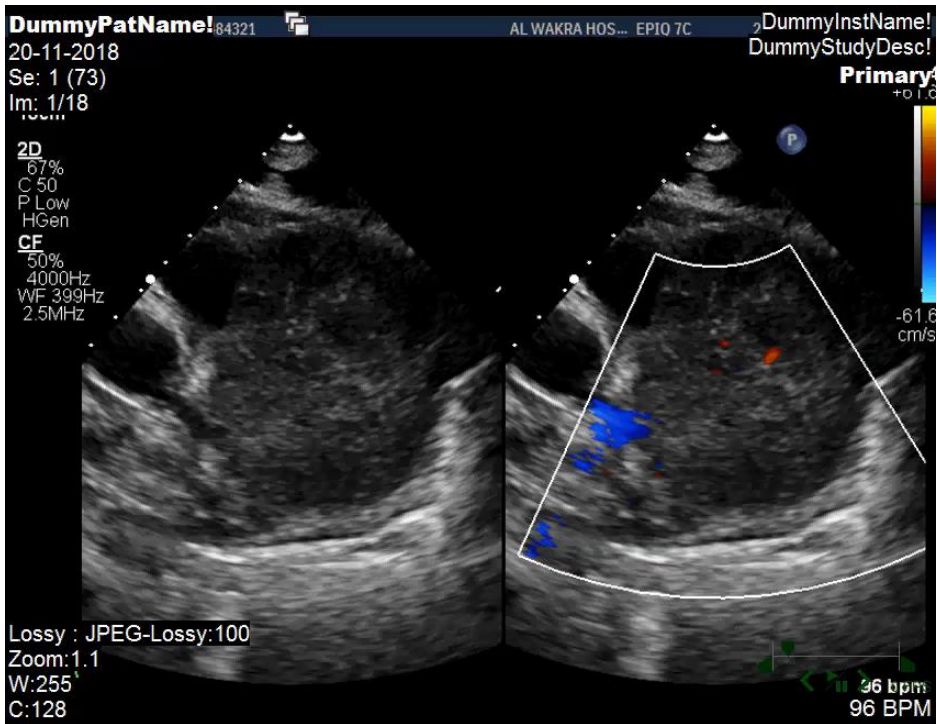
#1527

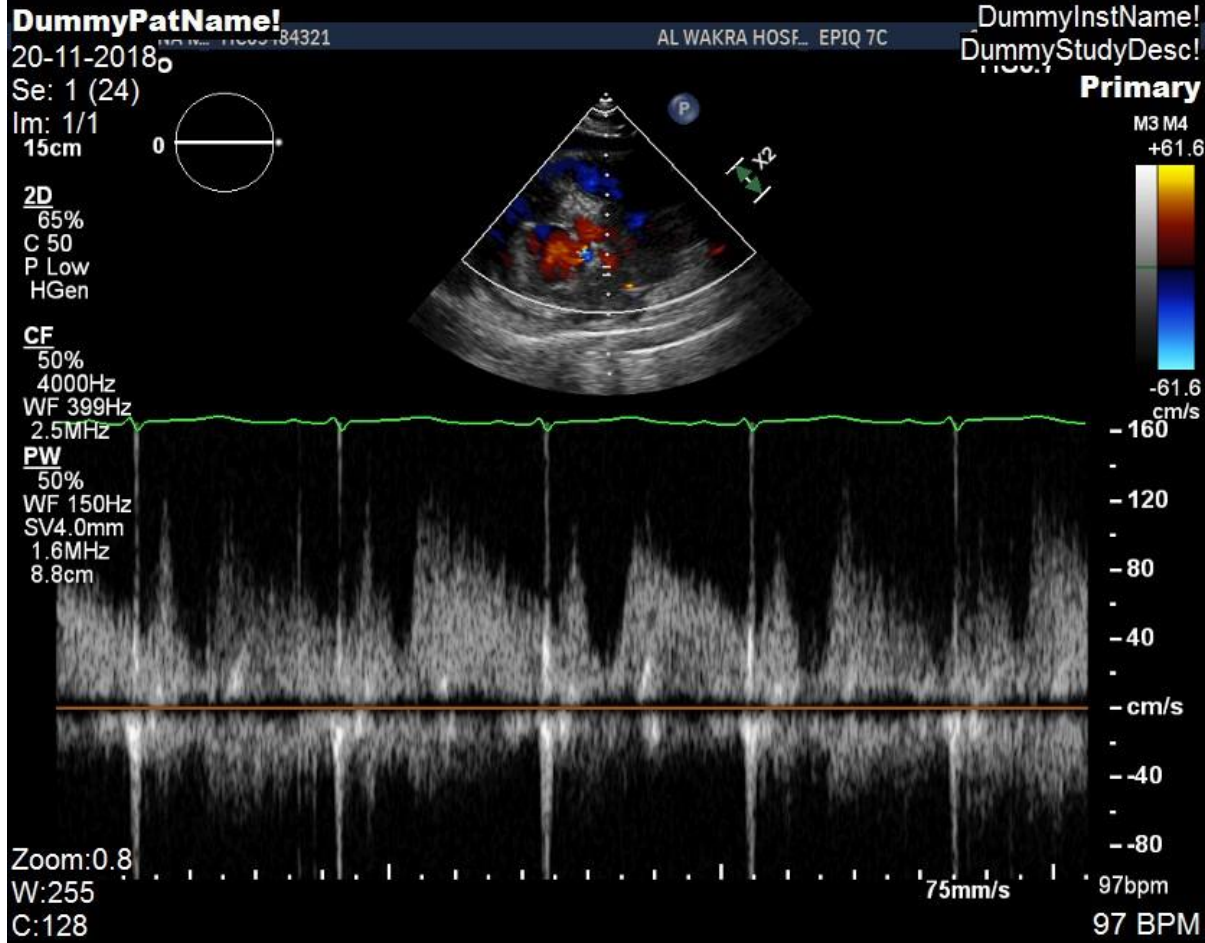
Unconfirmed Diagnosis

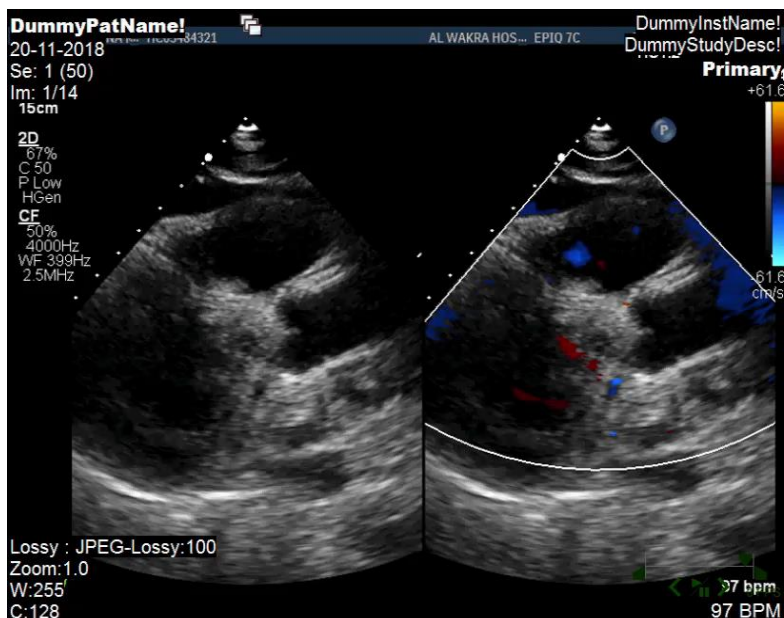
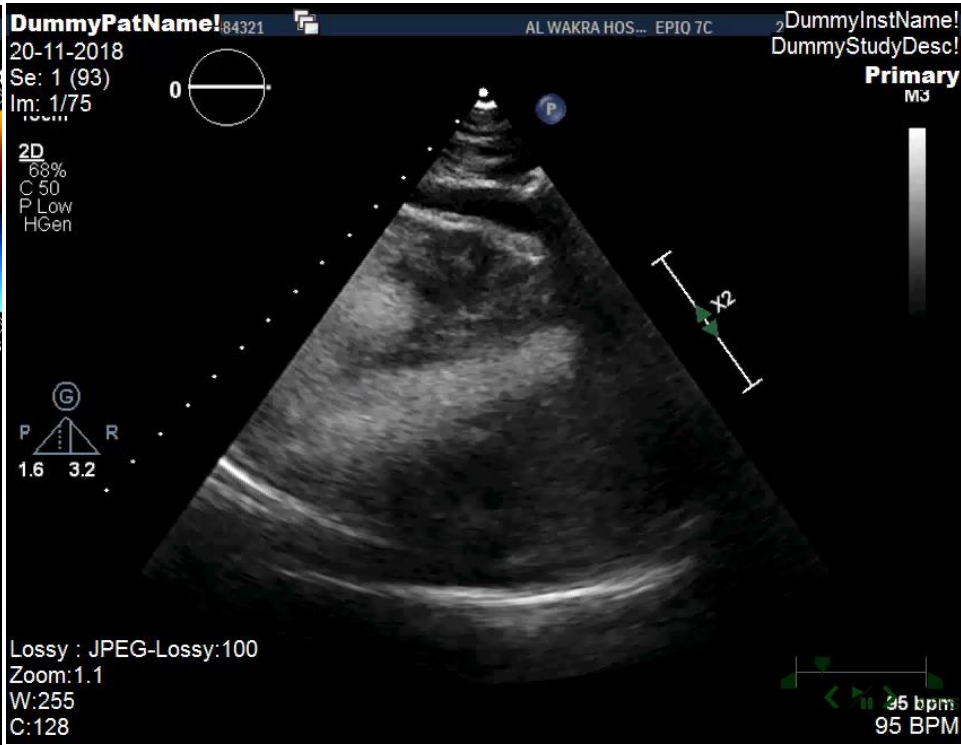
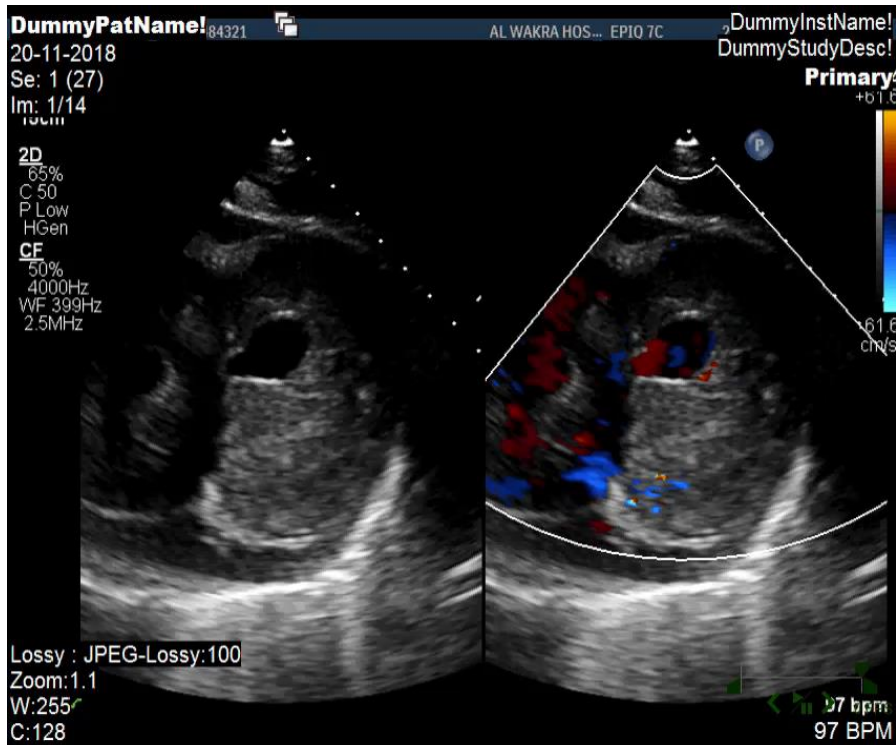
Dr. Saloom Hamdan Salem
Specialist, Cardiology/WH - HSC
049013

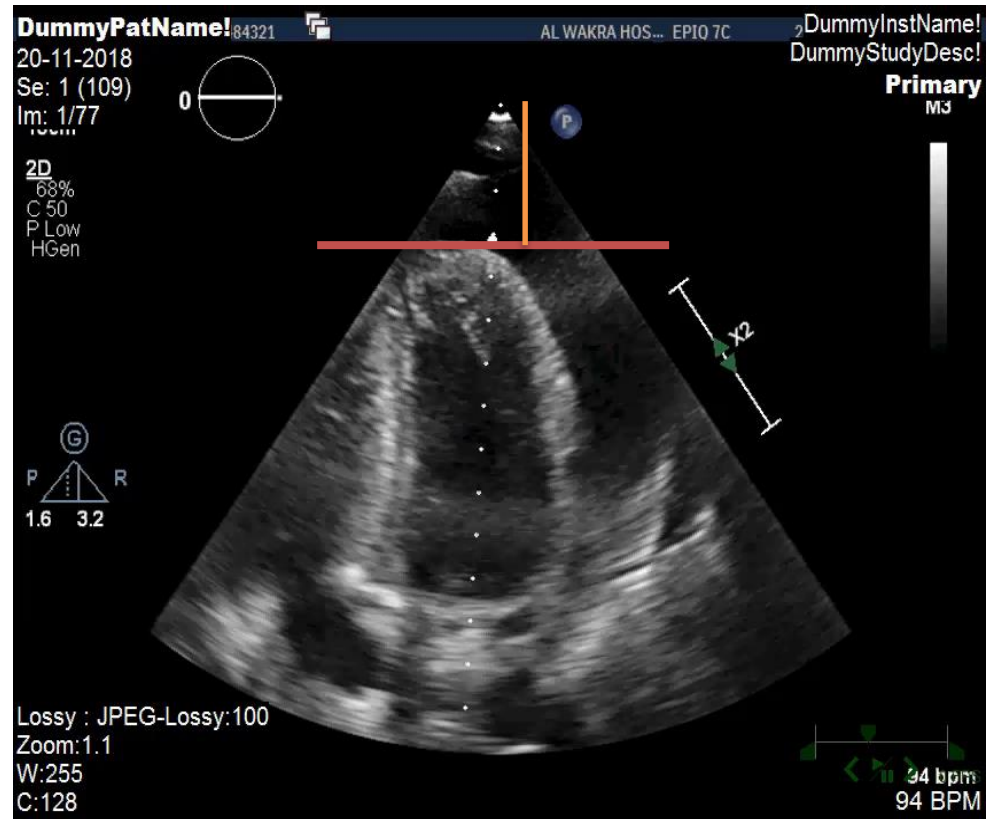
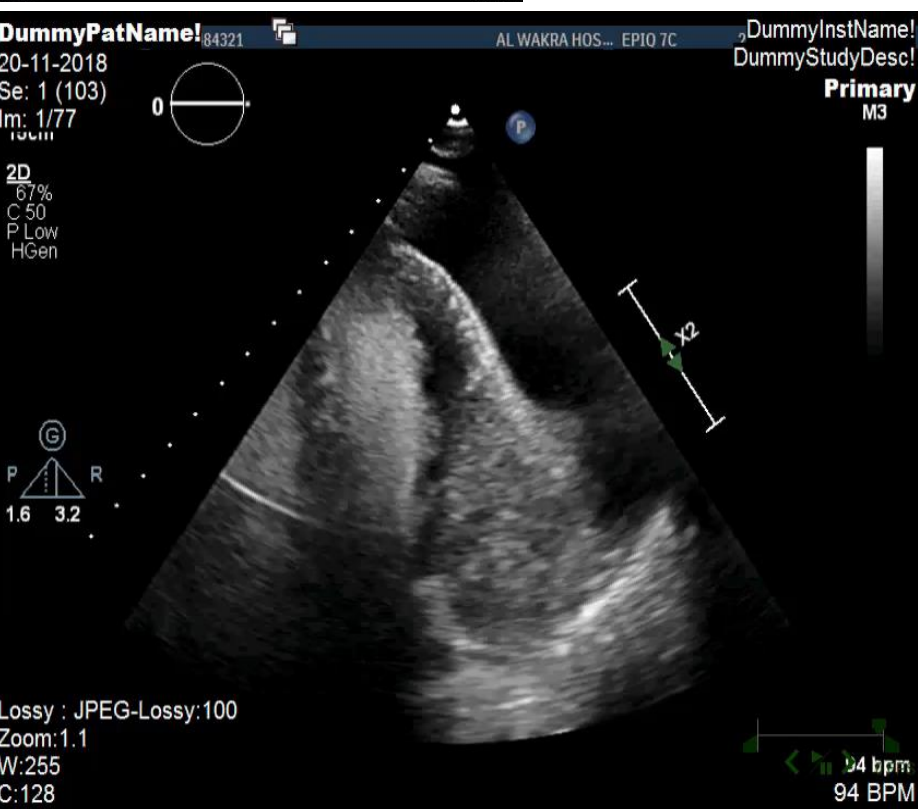
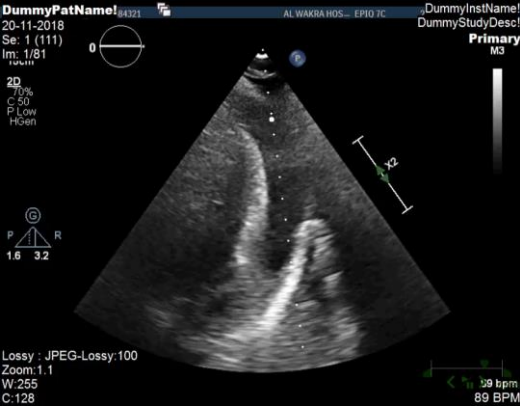











CONCLUSION//TAKE HOME MESSAGE

- TOMOGRAPHIC SCANNING.
- USE OPTISON.
- APICAL OR SUBCOSTAL.
- PROCEDURE IS GEOMETRIC MEASUREMENT.

NEEDLE = PROBE

ANGLE ON SKIN, DIRECTION, AND

DISTANCE TRAVELLED BY NEEDLE

THANK YOU